Aug. 26th to Aug. 28th, 2016

3rd European Aniridia Conference

Duisburg, Germany

Abstract Booklet

Compilation, design and ©: Prof. Dr. Barbara Käsmann-Kellner MD PhD 2016

GERMAN ANIRIDIA CENTER, DEPARTMENT OF OPHTHALMOLOGY, UNIVERSITY OF SAARLAND UKS
MEDICAL ADVISOR TO ANIRIDIE WAGR SUPPORT GROUP GERMANY WWW.ANIRIDIE-WAGR.DE

Supported by COST action BM1302

This page is intentionally left blank

TABLE OF CONTENTS

Thank you 5

To our sponsors and to all supporters 5

Program Outline 7

Saturday August 27th, 2016 8

Clinical Ophthalmology – History of Aniridia and Ophthalmology of Aniridia 8

Spectrum of Ophthalmological Findings in *PAX6* Related Aniridia 8

Clinical findings in Aniridia without PAX6 mutation 9

Clinical features of Korean aniridia patients with and without PAX6 mutation 10

History and future of aniridia 11

Genetics 13

PAX6 and other Genes: Mutations and Phenotypes 13

Genetics of congenital aniridia 14

The Mutation Spectrum and Functional Analysis Identified Novel *PAX6* Intronic Variants in Russian Aniridia Patients 15

Official Opening of the 3rd European Aniridia Conference 16

Developmental and Cellular Biology 17

Latest Developments in RNA Therapies for Aniridia 17

Increased TSH-producing cells in the pituitary gland of Pax6 haploinsufficient mice 18

Molecular anatomy of the limbal stem cell niche 19

Experimental Ophthalmology and Members of COST 20

Transport of cultured limbal epithelial cells for limbal stem cell transplantation 20

Imaging limbal stem cell niche degradation and progression of aniridia related keratopathy in several patient cohorts 21

Role of stromal stiffness in maintaining corneal epithelial phenotype: importance to homeostasis and corneal bioengineering 22

Current and future European research on rare and complex ocular surface diseases (e.g. Aniridia) 23

Aniridia research in clinical environment. Opportunities and disadvantages in research process 23

Clinical Ophthalmology: Cornea 25

Corneal diagnostic tools for ocular surface disease 25

Boston-keratoprosthesis: Preliminary experiences in high-risk eyes from the Department of Ophthalmology of the University of Cologne 25

Excimer-PTK and Keratoplasty in Congenital Aniridia 26

Neuroscience, Low Vision Aspects, quality of life 27

Foveal morphology in PAX2 and early visual development in foveal hypoplasia 27

LOW VISION CARE IN ANIRIDIA PATIENTS: POTENTIAL AND CHALLENGES 28

Ocular surface problems in aniridia – patients' experiences 30

Living with aniridia – the view of affected persons 31

Sunday August 28th, 2016 34

WAGR Syndrome & Wilms Tumor, metabolic alterations in PAX6 haploinsufficiency 34

WAGR syndrome: Guidelines for Clinical Management 34

Role of brain-derived neurotrophic fact in obesity, intellectual disability, and impaired nociception in patients with WAGR syndrome 35

Wilms Tumor: Treatment Protocols and Quality of Life 35

Ophthalmological challenges in WAGR patients 37

Sleep disturbances in PAX6 haploinsufficiency 39

Clinical Ophthalmology: Cataract & Glaucoma 40

Cataract in aniridic patients: special features and personal experience 40

Evaluation of provided indications for an artificial iris implantation and risks of artificial iris implantation in case of congenital aniridia 41

Glaucoma and Cataract surgery in aniridia with an emphasis on glaucoma tube surgery 43

Secondary glaucoma in congenital aniridia: Anatomy of the anterior chamber angle and consequences for trabeculotomy / cyclophotocoagulation 43

Concluding Session with question time for listening patients & Farewell 44
Summaries of the scientific talks (in German) 44
Options to ask questions to the attendant clinical and scientific researcher 44
Zusammenfassungen der wesentlichen Ergebnisse der wissenschaftlichen Vorträge 44
Möglichkeiten, den anwesenden Klinikern und Laborforschern Fragen zu stellen 44
Aniridia and soccer – Tribute & Thank you to 1. FC UNION Berlin, Soccer Club, 2nd Bundesliga 45
Concluding remarks and Thank you 47

Poster Abstracts & Information on Aniridia and Sports 48

Regeneration of the anterior cornea through a transplantation of cultivated limbal epithelial stem cells: Early results of a phase II clinical trial 48
Long term follow-up of patients with congenital aniridia 49
Aniridia: Sports and Daily Life 50

Contact informations of the first Speakers, sorted alphabetically 52

Aniridia Associations in Europe 57

THANK YOU

TO OUR SPONSORS AND TO ALL SUPPORTERS

WE CORDIALLY AND SINCERELY THANK OUR SPONSORS TO HELP MAKING THE 3RD EUROPEAN ANIRIDIA CONFERENCE A REALITY:

SOCCER CLUBS

- **1. FC Union Berlin**
  - **https://www.fc-union-berlin.de**
- MSV Duisburg
  - http://www.msv-duisburg.de
- VFR Aalen
  - http://www.vfr-aalen.de

1. FC Union Berlin **MSV Duisburg** **VFR Aalen 1921 e.V.**

Many individual Sponsors and Friends whithout whom nothing would have been possible:

- The many unnamed sponsors who supported our online StartNext Campaign to partly finance the conference
- Graf family
- Dausch family
- Steve Dlugos, crazy friend, keeper of a stiff upper lip, financial treasure trove, seer in the chaos, practical hand in every Conference aspect and Unioner as well
- Roland Krispin with his song “Wir sind Union”
- All **speakers** who have generously donated their travel costs!

Sponsoring Organisations

- COST Action BM1302
  - http://www.cost.eu/COST_Actions/bmbs/BM1302
- Travel Agency SchauInsLand Reisen Duisburg
  - http://www.schauinsland-reisen.de
- Aniridia Europe AE
- Stiftung Lederle
  - http://www.lederle-stiftung.org
- Firma Ursapharm, EvoTears ® , Saarbrücken
  - http://www.ursapharm.de

COST Action BM 1302

Reiseagentur SchauInsLand Reisen Duisburg

Aniridia Europe

Stiftung Lederle, Taufkirchen

Firma Ursapharm Arzneimittel GmbH, Saarbrücken

3rd European Aniridia Conference
and
Patient´s Day, Duisburg, Germany

Location: Schauinsland-Reisen Travel Agency Headquarter, Stresemannstr. 80, 47051 Duisburg

PROGRAM OUTLINE

Friday, 26th of August	**Patient´s Day (13:00 – 18:00)**	**Patiententag (13:00 – 18:00)**
	3rd Scientific European Aniridia Conference	**3. Europäische Wissenschaftliche Aniridie-Tagung**
Saturday, 27th of August		
09:00 – 10:40	General ophthalmological manifestations of aniridia, Genetics	Allgemeine Augenbeteiligungen bei Aniridie, Genetik
11:00 – 11:20	Official opening of the 3rd European Aniridia Conference	Offizielle Eröffnung und Begrüßung zur 3. Europ. Aniridietagung
11:20 – 12:30	Developmental and cellular biology	Zelluläre und entwicklungsbezogene Biologie
12:30 – 13:30	Lunch and Poster presentation, Information: Aniridia: Sports&Life	Mittagsimbiß und Postervorstellung, Information: Aniridie&Sport
13:30 – 15:15	Experimental Ophthalmology	Experimentelle Ophthalmologie
15:45 – 18:15	Clinical Cornea, Neuroscience and Low Vision, Quality of Life	Klinische Hornhautthemen, Sehbehinderung, Lebensqualität
19:00	Closed Session: Lecturers´ dinner with AWS & AE representatives	Geschlossene Veranstaltung: Abendessen Referenten, AWS, AE
Sunday, 28th of August		
09:00 – 10:25	WAGR – Syndrome & Wims Tumor	WAGR – Syndrom & Wilms Tumor
10:45 – 12:00	Cataract and Glaucoma in Aniridia	Katarakt und Glaukom bei Aniridie
12:00 – 13:00	Lunch and Poster presentation Information: Aniridia: Sports&Life	Mittagsimbiß und Postervorstellung Information: Aniridie&Sport
13:00 – 16:00	Summary of important conference messages for patients (in German), announcements (e.g. 4th European Aniridia Conference in Paris), acknowledgements of sponsors and supporting organisations, closing remarks and Farewell	Zusammenfassung wichtiger Tagungsergebnisse (auf Deutsch), Vor-Ankündigungen (zB 4. Europäische Aniridie-Konferenz in Paris), Danksagungen an Sponsoren und unterstützende Organisationen, Schlussworte und Verabschiedung

ABSTRACTS

For your notes

SATURDAY AUGUST 27TH, 2016

CLINICAL OPHTHALMOLOGY – HISTORY OF ANIRIDIA AND OPHTHALMOLOGY OF ANIRIDIA

SPECTRUM OF OPHTHALMOLOGICAL FINDINGS IN *PAX6* RELATED ANIRIDIA

Erlend Sommer Landsend
Department of Ophthalmology, Oslo University Hospital, Norway

The paired-box gene *PAX6* is the major gene responsible for development of aniridia. Different mutations in the gene could give various aniridia phenotypes. Missense mutations in the *PAX6* gene usually predict a milder phenotype, with less severe visual loss. Mutations leading to a premature termination codon, on the other hand, usually cause a more severe aniridia phenotype, with marked visual impairment. Aplasia or hypoplasia of the iris is the characteristic hallmark of aniridia at birth. The iris changes could be subtle in some cases. Macular hypoplasia is the second most common congenital finding. Optic nerve hypoplasia is less frequent. The congenital features usually lead to photophobia, significant reduced vision and nystagmus. Visual acuity is usually from 20/100- 20/200. Development of secondary, progressive ocular disorders is common later on. These disorders include cataract, aniridia related keratopathy and glaucoma.

CLINICAL FINDINGS IN ANIRIDIA WITHOUT PAX6 MUTATION

Barbara Käsmann-Kellner

German Aniridia Center at the Department of Ophthalmology, Saarland University Medical Center UKS, Homburg/Saar, Germany

Background: As of 08/2016, we care for 196 patients with aniridia at the German Aniridia Center at the Saarland University Medical Center in Homburg/Saar. Especially concerning older patients, molecular genetic analysis has not always been performed. This report describes the changes in those patients who have had analysis of PAX6 and do not show mutations in that region.

Patients: Within the 196 patients, n = 75 have PAX6 related dominant aniridia. Another 14 patients have WAGR syndrome, and 32 patients with (up to now) sporadic aniridia have been tested positive for PAX6 mutations. This leads to n = 121/196 patients with defined mutations of PAX6. From the remaining 75 patients, n = 48 did not yet have molecular genetic analysis. 13 patients have been analyzed and show other genetic or chromosomal anomalies with no PAX6 abnormality. Another 14 patients have been analyzed with no PAX6 mutations and no other causative mutation, eg P *ITX2* (4q25), *FOXC1* (6p25), *SOX2* (3q26) were found up to now.

Results: We are presenting the 27 patients in whom PAX6 analysis revealed no mutations.
Concerning the group with other genetic or chromosomal findings related to aniridia, there was the following distribution:

<u>13 Patients with other aniridia related genetic findings:</u>

- Molecular genetic findings:
  - Peters syndrome 1x *CYP1B1* (2p22.2),
  - Peters plus 2x *PITX2* (4q25),
  - Rieger syndrome 3x *PITX2* (4q25), *FOXC1* (6p25),
  - CHARGE Association 1x *CHD7-Gen* (8q12.1),
  - Marinesco-Sjögren-Syndrome 1x *SIL1*-Gen (5q31),
  - Mutation of *ELP4-Gen* (Chr11) ELONGATOR ACETYLTRANSFERASE COMPLEX, SUBUNIT 4
- Microdeletions:
  - One patient with two microdeletions: Chromosomes 2p21.3, 12p14.3
  - One patient with microdeletion on chromosome 20, site not specified

- Balanced Translocation:
  - 1x, between Chr. 5 and 11
- Numeric chromosomal aberrations
  - Trisomy 13 1x (Pätau-Syndrome)

14 Patients with no mutation in PAX6 and no other mutations found in aniridia related genes like *PITX2* (4q25), *FOXC1* (6p25), *SOX2* (3q26)
There was an interesting spectrum of patients which included 2 sisters with severe microphthalmia and aniridia (*SOX2* neg), a twin boys couple with incomplete aniridia and beginning LSCI, one family where one son had a PAX6 mutation, but his sister with extensive colobomata and microphthalmia had not, and his mother with aniridia and microphthalmia on one side and anophthalmia on the other side did as well not have PAX6 mutations. In addition, there are three patients with typical aniridia and aniridia related complications plus albinism, proven by Albino-VEP. One girl has complete aniridia and suffered from congenital glaucoma with opacified corneae at birth. The last three patients without PAX6 mutations have complete aniridia with very good visual acuity and no nystagmus.

Conclusions: Patients with aniridia and no PAX6 mutations show a wide spectrum of involved genes and sometimes chromosomal aberrations. Peters syndrome and Rieger syndrome are the most frequently found genetic grounds for the present complete or incomplete aniridia. Concerning the group of patients without PAX6 mutations and without mutations in *PITX2* (4q25), *FOXC1* (6p25), *SOX2* (3q26) there is a very variable clinical phenotype ranging from aniridia combined with severe microphthalmia and even anophthalmia, a combination of typical aniridia with VEP proven albinism and patients who present with complete aniridia and do not show any aniridia-related complications and a very good visual acuity.

Clinical features of Korean aniridia patients with and without PAX6 mutation

Lim Hyun Taek, MD, PhD
Department of Ophthalmology, Asan Medical Center, University of Ulsan College of Medicine, Seoul, Korea

Purpose: To present the clinical features of Korean aniridia patients with and without PAX6 mutation.

Methods: A retrospective, observational case series study. The diagnosis of congenital aniridia was made based on the combination of clinical findings including variable degree of iris hypoplasia, macular hypoplasia, and associated ocular anomalies. Clinical data on the severity of iris hypoplasia, macular hypoplasia, nystagmus, cataract, and keratopathy were collected together with the visual acuity and the Optical Coherence Tomography (OCT) findings. The results of PAX6 gene mutation analysis and the multiplex ligation-dependent probe amplification testing were also described.

Results: A total of 28 patients from 18 unrelated families were included in the present study. Best corrected visual acuity of the patients varied widely from hand motion to 20/25. The degree of nystagmus was also quite variable; barely detectable in 3 patients, although large amplitude pendular type in a majority of patients. All but one patient had severe macular hypoplasia. Patients harboring an identifiable mutation in PAX6 had either a severe or a mild phenotype. Likewise, the patients without PAX6 mutation demonstrated a wide spectrum of phenotypes from severe to very mild.

Conclusion: Congenital aniridia is a serious, sight-threatening ocular malformation having a broad spectrum of clinical phenotypes. No specific differentiating clinical features could be revealed, in this study, between patients with and without PAX6 mutations.

HISTORY AND FUTURE OF ANIRIDIA

Jens Martin Rohrbach

Department für Augenheilkunde/Center for Ophthalmology, University of Tuebingen, Schleichstr. 12-16, D-72076 Tübingen, Germany

The history of aniridia is crucial for the understanding of the disease. Aniridia was probably first described by Alex Morison in 1819 in the publication “Observation sur un enfant dont les yeux n’avaient point d’iris” (“Observations on a child whose eyes had no iris”). In the beginning 19th century the term “Irideremia” (“Lack or loss of iris”) was favoured which is – as the iris is almost never completely absent - morphologically more correct than the term “Aniridia” (“Absence of iris”) which was preferred from 1844 on. Until today, aniridia has its place in almost all textbooks dealing with ophthalmology and ophthalmological teratology. Many famous ophthalmologists like Friedrich August von Ammon (1799-1861, Germany), Thomas Wharton Jones (1808-1891, England), Wilhelm Manz (1833-1911, Germany), Ernst Fuchs (1851-1930, Austria), Alfred Vogt (1879-1943,

Switzerland), Ida Mann (1893-1983, England), and Günther Badtke (1910-1967, Germany) have delivered more or less detailed descriptions. Thus, aniridia is definitely not "unknown". As differential diagnosis is usually limited and easy, a wrong diagnosis of aniridia, as some parents seem to have experienced, reflects more likely a problem of ophthalmological education.

Friedrich August von Ammon, 1841

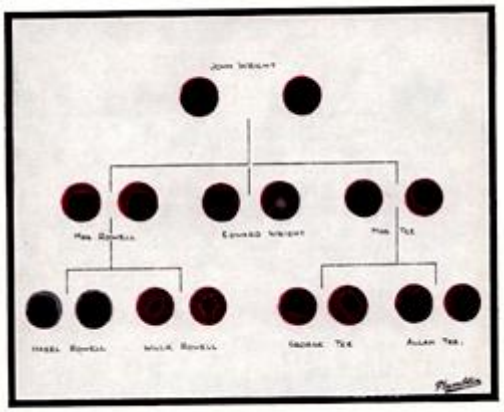

Fig. 142. The pupils of the various members of an aniridic family.

Ida Mann, 1957

There is aniridia research since the middle of the 19th century with more and more precise clinical and morphological reports. The most influential publication was probably Richard Seefelder's "Aniridia as a developmental suppression of the retina" from 1909. Although hypoplasia of the macula was already known at that time Seefelder was the first to discover that aniridia is not confined to the iris but represents a syndrome affecting all sections of the inner leaf of the eye cup. Taking the normal embryology into account, the development of the macula is arrested in the 7th month of pregnancy in aniridic eyes so that no normal fovea is formed. The structural changes in the chamber angle explain glaucoma, the underdevelopment of the ciliary body increases very likely the risk of hypotony after trabeculotomy or

cyclodestruction. Loss of lens transparency is probably caused by altered and reduced aqueous flow. Hardly to explain with Seefelder's embryological concept is limbal stem cell deficiency. Another milestone was the publication of the aniridia – Wilms' tumour – association in 1964 by Robert Miller and coworkers. So aniridia research has as yet been performed on a quite remarkable scale.

Aniridia is not curable but treatable. Its future management will profit from progresses in other fields of ophthalmology like glaucoma, cataract extraction, iris replacement, corneal transplantation, and stem cell therapy. Whether the arrest of macular development will be overcome by gene therapy has to be awaited but this will be, if ever happening, still a very long way. Iris transplantation will almost surely be unsuccessful even in the far future because of immunological and especially anatomical reasons. Nevertheless, aniridia research will go on and it should be further supported. In so far Union Berlin's sponsoring with selling of paintings created by children is absolutely valuable. But even more valuable than the money is the human aid and empathy for affected patients and their parents which emerge out of these campaigns.

GENETICS

PAX6 AND OTHER GENES: MUTATIONS AND PHENOTYPES

Veronica van Heyningen

Veronica van Heyningen CBE FRS, Patron, Aniridia Network UK. Honorary Professor and Visiting Scientist Institute of Ophthalmology, University College London & MRC Human Genetics Unit Institute of Genetics and Molecular Medicine Edinburgh, United Kingdom

Aniridia is most often caused by the functional loss of one copy of the regulatory gene PAX6. PAX6 is a key gene controlling the expression of other genes needed for normal eye development. PAX6 mutations can generally be identified in 85-90% of aniridia cases. In most "classical" aniridia cases, one copy of the PAX6 gene produces no working protein. In smaller proportion of cases the protein is there but its major active domain or its tail end is abnormal and in 10% of cases there is a change to just one amino acid of the

protein, which can lead to somewhat different phenotypes, some milder, others more severe, than classical aniridia. In a few rare cases aniridia, often with congenital or very early onset glaucoma, is associated with mutations in one or two other eye development genes, such as FOXC1 or PITX2. Recently a new gene was shown to be responsible for a very rare aniridia-like iris abnormality which is also accompanied by central movement and body-tone problems. PAX6 mutations also affect some aspects of brain development and function but most aniridia patients compensate automatically for these problems and those with aniridia generally show very good attainment at school and later. But understanding what is happening to the eye, brain and perhaps also the pancreas – which also needs PAX6 for its development and maintenance – may allow us to slow down or prevent disease progression.

GENETICS OF CONGENITAL ANIRIDIA

Hanno Bolz

Deputy Medical Director, Center for Human Genetics, Bioscientia, 55218 Ingelheim, GERMANY

Background: Mutations in the PAX6 gene mostly cause non-syndromic aniridia with autosomal dominant inheritance and familial occurrence. The underlying point mutations and deletions in the PAX6 locus cause loss-of-function of one gene copy (haploinsufficiency). Mutations with residual PAX6 function often result in milder disease expression but may also cause distinct and more severe ocular phenotypes. Combined deletion of PAX6 and the adjacent WT1 tumor suppressor gene causes Wilms tumor, aniridia, genitourinary anomalies and mental retardation (WAGR) syndrome with a high risk for Wilms tumors in infancy.

Purpose: Genetic diagnostics are important for confirming the clinical diagnosis, for the assessment of the risk of recurrence and early recognition of children with associated tumor risk.

Results and Discussion: Sequencing of the PAX6 gene and quantitative analysis of the PAX6 locus allow for efficient molecular genetic evaluation of the clinical diagnosis of both isolated and syndromic aniridia. In cases of clinical overlap with other entities, high-throughput sequencing of multiple additional genes can simultaneously cover genes for differential diagnoses (e.g. microphthalmia syndromes). Optimal care of aniridia patients requires close cooperation of ophthalmologists and medical geneticists.

The Mutation Spectrum and Functional Analysis Identified Novel *PAX6* Intronic Variants in Russian Aniridia Patients

Tatyana A. Vasilyeva[1], Alexandra Yu. Filatova[1], Anna A. Voskresenskaya[2], Olga V. Khlebnikova[1], Nadezhda A. Pozdeyeva[2], Barbara Käsmann-Kellner[3], Mikhail Yu. Skoblov[1,4], Andrey V. Marakhonov[1,4], Rena A. Zinchenko[1,5]

[1]Federal State Budgetary Institution «Research Center for Medical Genetics», Moscow, Russian Federation. [2]Cheboksary branch of S. Fyodorov Eye Microsurgery Federal State Institution, Cheboksary, Russian Federation. [3]Section Paediatric Ophthalmology, Orthoptics, Low Vision & Neuroophthalmology, Department of Ophthalmology, Saarland University Medical Center *UKS*, Homburg/Saar, Germany. [4]Moscow Institute of Physics and Technology (State University), Moscow. [5]Pirogov Russian National Research Medical University, Moscow, Russian Federation.

Mutation analysis and detailed clinical evaluation were performed in 107 patients with clinical aniridia from Russia. 52 patients had a confirmed dominant inheritance of disorder and 1-2 affected family members. 11 patients showed microdeletion consistent with WAGR syndrome (7 confirmed and 4 suspected under 1 year). 3 patients showed neither mutations in *PAX6* nor microdeletions of 11p13 region. They will undergo NGS. Therefore, we present the results of 114 patients with *PAX6* mutations out of 117 analyzed aniridia patients.

Screening for mutations in *PAX6* was carried out by initial Sanger sequencing analysis followed by Multiplex Ligation-dependent Probe Amplification (MLPA) and Loss Of Heterozygosity (LOH) analysis using short-tandem-repeat (STR) markers.

A total of 88 different mutations (58 small and 30 large deletions, counting one mutation per family) are found. 15 non-related probands share the same mutations. 28 probands with small intragenic mutations and all probands with large deletions (30) have mutations which had not been described elsewhere up to now. So here, we have got 67,4% probands with novel mutations in total.

A high proportion of canonical splice site mutations and mutations of distanced intronic splicing regulatory sequences are identified in this cohort (11 different mutations in 18 patients). Intronic and splicing variants were analyzed using Human Splicing Finder tool v. 2.4.1 and IntSplice. Variants' pathogenic status was established using the consensus recommendation of the American College of Medical Genetics and Genomics (ACMG) and the Association for Molecular Pathology for interpretation of sequence variants. In order to test 2 variants of unknown significance (VUS) and other distanced intronic variants the molecular functional analysis was carried out. One of the VUSs – substitution NG_008679.1(PAX6_v001):c.142-14C>G, - had been predicted to affect normal splicing. To reveal consequences of normal and altered splicing pattern of the *PAX6* gene caused by the intronic SNV we have used exon trapping assay. Wild type and mutant SNVs containing intron 5 with cassette exon 5a, flanked by neighbor exons 5, and 6, and 7, and their adjacent introns were cloned into the plasmid pCtrlPIG between two reporter genes. Then constructs were transfected into HEK293T cell line. Splicing products were then identified with RT-PCR using primers flanking insert. This resulted in several amplicons corresponding to the products of splicing pattern. Wild type allele of this SNV generated the splicing pattern as follows: exons 5–6–7 as predicted. In contrast, mutant allele led to switch of intron 5 acceptor site to the new position distanced 13 nucleotides inwards intron sequence.

Thus we have confirmed pathogenic character and causative role of one of the deep intronic variants in *PAX6*. Our study emphasizes the importance of in-depth search for *PAX6* mutations especially in cases of fine aniridia phenotype.

Official Opening of the 3rd European Aniridia Conference

Denice Toews-Hennig, President **A**niridie-**W**AGR **S**upport Group Germany **AWS**

Asbjørn Akerlie, Norway, President of Aniridia Europe **AE**

Barbara Käsmann-Kellner, German Aniridia Center at the Department of Ophthalmology, University of Saarland, Medical Advisor **AWS**

Manfred Osenger, Governing Mayor of the City of Duisburg

DEVELOPMENTAL AND CELLULAR BIOLOGY

LATEST DEVELOPMENTS IN RNA THERAPIES FOR ANIRIDIA

Cheryl Y Gregory-Evans and Naif Sannan

University of British Columbia, Vancouver, Canada

Although there are a number of potential approaches to treat aniridia such as gene therapy and stem cell replacement, these are still associated with a number of problems and have not yet reached the clinical setting. RNA therapy is a novel and attractive option as it avoids the problems associated with standard gene therapy such as poor control of gene expression and the potential for damaging the genome. Using this approach, we have established RNA nonsense suppression therapy for a variety of ocular diseases including aniridia, choroideremia, ocular coloboma. A brief synopsis will be provided regarding the current clinical trial in aniridia. To address the other gene mutations in aniridia that are not suitable for nonsense suppression, we are now evaluating SMaRT technology (spliceosome-mediated RNA *trans*-splicing) to replace damaged RNA with an artificially engineered molecule to produce normal protein and thereby inhibit disease progression. RNA therapies have the advantage of maintaining endogenous gene regulation and elimination of ectopic gene expression. To test this approach we are applying SMaRT therapy delivered to a mouse model aniridia (*Pax6-Sey*). RNA *trans*-splicing modules (RTMs) were designed to intron 1 of mouse *Pax6 as* this will capture any mutation downstream of exon 1. The RTM consists of (i) a binding domain, that is complementary to 150 nucleotides of pre-mRNA intron 1; (ii) an intron sequence containing a branch point, a polypyrimidine tract and a 3' acceptor splice site; (iii) replacement exons of the *Pax6* cDNA without the known mouse mutations and a FLAG tag, cloned into an expression vector. Efficiency of each RTM was tested in COS-7 cells expressing the mutant gene sequence. Initial results in cell culture suggest that an oligonucleotide is required to block the normal *cis*-splicing to improve efficiency of *trans*-splicing. Proof-of-principle for aniridia *in vivo* will next be tested in mouse cornea using a non-viral delivery approach.

INCREASED TSH-PRODUCING CELLS IN THE PITUITARY GLAND OF PAX6 HAPLOINSUFFICIENT MICE

Kenji K. Johnson[1], Anastasia M. Bobilev[2], Khan Hekmatyar[3], and James D. Lauderdale[1,2]

[1]Department of Cellular Biology, [2]Neuroscience Division of the Biomedical and Health Sciences Institute, [3]Bio-imaging Research Center, The University of Georgia, Athens, GA 30602, USA

Aniridia is a congenital condition characterized by absence of iris and is caused by a semidominant mutation in the transcription factor encoded by the *Pax6* gene. Although ocular phenotypes of this disorder are well characterized, recent studies report that individuals with aniridia have a higher propensity for obesity, infertility, polycystic ovarian disease, and severe eczema compared to their *Pax6*-normal siblings. These symptoms collectively suggest an underlying endocrine disturbance related to haploinsufficient levels of *Pax6*.

In mice, during development, *Pax6* expression in the pituitary gland begins at E9.0 in the primordial anterior pituitary gland (Rathke's Pouch). This expression becomes restricted to the dorsal anterior pituitary by E11.5, but is expressed throughout the anterior lobe by E14.5, and remains through adulthood.

It is possible that a reduction in *Pax6* could result in a change in pituitary hormone levels or cell numbers, which may explain symptoms experienced by aniridics. Using the *Small eye* mouse model, we find that *Pax6* reduction results in a decrease in GH-producing cells and an increase in TSH-producing cells in neonate mice, with the TSH increase continuing into adulthood.

Adult *Pax6* haploinsufficient mice also have an increase in anterior pituitary volume and weigh significantly less than their wild-type littermates. Furthermore, we show that the increase in TSH-producing cells leads to an increase in thyroxin (T_4) in mutant mice, although tri-iodothyronine (T_3) levels remain unchanged. These findings present a new role for *Pax6* in the endocrine system, which serves to refine our current understanding of *Pax6* in endocrine development and maintenance and provides new avenues for investigating endocrine-related symptomatology in aniridia.

MOLECULAR ANATOMY OF THE LIMBAL STEM CELL NICHE

Ursula Schlötzer-Schrehardt

Department of Ophthalmology, Friedrich-Alexander University Erlangen-Nuremberg, Erlangen, Germany

Maintenance and regeneration of the corneal epithelium relies on unipotent progenitor cells at the corneoscleral limbus, which are regulated by extrinsic factors from their local microenvironment, the stem cell niche. The postulated limbal niche is an anatomically protected site of intimate epithelial-mesenchymal interaction and is highly vascularised, innervated, pigmented due to intraepithelial melanocytes, infiltrated with immune cells, and supported by a specialized extracellular matrix as well as subepithelial mesenchymal cells emitting soluble signals. For ex vivo expansion and transplantation, limbal stem cells are unfavourably removed from their niche. This lecture outlines our current understanding and novel findings regarding the structural and molecular composition of the limbal niche including different niche cell populations, specific matrix components, cell-matrix- and cell-cell adhesion molecules, which are involved in stem cell regulation through multiple signalling pathways. This lecture also provides an overview of current tissue-engineering approaches for corneal surface regeneration that aim at incorporating specific niche components, such as matrix proteins, growth and signalling factors, or putative niche cells, into the culture systems in order to support maintenance of stemness and to improve the therapeutic use of limbal stem cell transplantation.

EXPERIMENTAL OPHTHALMOLOGY AND MEMBERS OF COST

LIMBAL STEM CELL DEFICIENCY (LSCD)

Tor Paaske Utheim

Department of Oral Biology, Faculty of Dentistry, University of Oslo, Oslo, Norway; Department of Medical Biochemistry, Oslo University Hospital, Oslo, Norway; Department of Ophthalmology, Drammen Hospital, Vestre Viken Hospital Trust, Drammen, Norway; Faculty of Health Sciences, University College of South East Norway, Kongsberg, Norway.

The cornea is essential for normal vision by maintaining transparency. The stem cells of the epithelial layer of the cornea is believed to harbour in its periphery, termed limbus. Any damage or disease affecting the function of these limbal stem cells may result in limbal stem cell deficiency (LSCD). The condition may result in severe pain and blindness. The condition can be treated by means of several cell based approaches. Recently, alternative therapies not involving cells have emerged. The present talk gives a brief overview of some treatment modalities for LSCD.

TRANSPORT OF CULTURED LIMBAL EPITHELIAL CELLS FOR LIMBAL STEM CELL TRANSPLANTATION

Øygunn Aass Utheim

Department of Ophthalmology, Oslo University Hospital, Oslo, Norway

Aniridia is one of many disorders that can lead to limbal stem cell deficiency, a condition where the corneal epithelium fails to regenerate due to lack of epithelial stem cells. In 1997 Pellegrini et al. showed that a small explant from a healthy region of the limbal zone of the ocular surface can be expanded in vivo, transplanted back to the diseased eye and re-establish the stem cell

population. However, many patients are not offered this type of treatment due to various causes. One reason is the need for advanced laboratory equipment and expertise in cell culture. Another is the risk of transferring harmful microorganisms from the cultured cells to the diseased ocular surface – which has to be minimised before treating vulnerable eyes like aniridic eyes. Our research group has developed a method for storage and transport of these cells. The idea is to centralize the laboratory part of the treatment in order to provide state of the art cultured epithelial cell sheets for the ophthalmologic surgical wards. We found that with our method, cultured limbal epithelial cells can be stored and also transported under xenobiotic-free conditions, in ambient temperature and under vigorous movements without losing its viability, phenotype or ultrastructure.

IMAGING LIMBAL STEM CELL NICHE DEGRADATION AND PROGRESSION OF ANIRIDIA RELATED KERATOPATHY IN SEVERAL PATIENT COHORTS

Neil Lagali[1], Bogumil Wowra[2] Dariusz Dobrowolski[2], Tor Paaske Utheim[3] Ulla Edén[1], Edward Wylegala[2], Per Fagerholm[1]

[1] Department of Ophthalmology, Institute for Clinical and Experimental Medicine, Faculty of Health Sciences, Linköping University, Sweden. [2] Ophthalmology Department II, School of Medicine, Division of Dentistry in Zabrze, Medical University of Silesia, Katowice, Poland. [3] Department of Ophthalmology, University of Oslo, Norway

Purpose: To investigate the morphology of the limbal stem cell niche, corneal epithelium and nerves during the progression of congenital aniridia related keratopathy.

Methods: Patient cohorts in Sweden, Norway, and Poland were examined using optical coherence tomography and in vivo confocal microscopy to document tissue and cellular-level changes during various stages of the development of keratopathy. In total, over 80 subjects with aniridia were examined. Slit lamp examination was performed and digital photographs were used to document the phenotypic appearance and to grade the stage of keratopathy according to a previously developed scale.

Results: Cohorts of aniridia subjects from different geographic regions and different families within a region appeared to have characteristic morphologic

findings in the cornea at the cellular level. Thin epithelia revealed an abundance of subbasal nerves in some subjects, while infiltration of dendritic cells in other subjects indicated an inflammatory state that correlated with nerve loss. The presence and morphologic appearance of structures of the limbal stem cell niche and cellular morphology in the niche region correlated with the stage of keratopathy, with degradation of the niche apparent in the very early stages. In some families, the limbal stem cell niche was totally absent even in early stages of keratopathy. Central corneal nerves and epithelial phenotype can persist despite the presence of keratopathy, and a model is proposed to explain the sequelae corresponding to limbal stem cell degradation.

Conclusion: An understanding of the phenotypic changes occurring in the corneal epithelium, nerves, and stem cell niche as aniridia related keratopathy develops may aid in elucidating the reasons for progression of keratopathy and deciding on the timing of interventions to preserve or restore corneal transparency.

ROLE OF STROMAL STIFFNESS IN MAINTAINING CORNEAL EPITHELIAL PHENOTYPE: IMPORTANCE TO HOMEOSTASIS AND CORNEAL BIOENGINEERING

Che J Connon[1], Ricardo M Gouveia[1], Ian W Hamley[2], Guillaume Lepert[3] and Carl Paterson[3]

[1] Faculty of Medical Sciences, Newcastle University, UK; [2]Dept. Chemistry, University of Reading, UK; [3]Dept. Photonics, Imperial College London, UK

We have hypothesized that the biomechanical properties of the corneal surface, directly beneath the corneal epithelium, plays a fundamental role in the tissue's homeostasis (i.e., the balance between epithelial cell migration, differentiation, proliferation, and desquamation). Previously we have demonstrated that collagen gels of different stiffness affect limbal stem cell differentiation and that markers of mechanosensitive differ centripetally across the cornea. Recently we used a non-contact high-resolution Brillouin spectro-microscopy to show, for the first time, that the matrix comprising the corneal limbus has significantly lower bulk modulus compared to that of the central cornea, and that this difference is precisely delimited in the organ. Furthermore, we show that areas of the limbus with distinctly softer properties were associated with limbal epithelial stem cell (LESC) residence.

We have subsequently applied this knowledge to the rational design of human stromal cell-derived tissue engineered contracts. Using a unique tissue-templating technology we can instruct keratocytes to make stromal equivalents with prescribed levels of collagen organization and elastic modulus.

Current and future European research on rare and complex ocular surface diseases (e.g. Aniridia)

Claus Cursiefen[1], Neil Lagali[2]

[1]Department of Ophthalmology, University Hospital of Cologne, Cologne, Germany. [2]Department of Ophthalmology, Institute for Clinical and Experimental Medicine, Faculty of Health Sciences, Linköping University, Sweden

In this talk we will present an overview of current pan-European networking opportunities and research projects focusing on ocular surface diseases, with a view towards building a support base for further European funding applications relevant to Aniridia. We will discuss strategies for the formation of research consortia building on current networks, projects, and expertise that can be leveraged to create pan-European research efforts investigating disease mechanisms and new therapies for aniridia.

Aniridia research in clinical environment. Opportunities and disadvantages in research process

Lorenz Latta [1], Barbara Käsmann-Kellner [1], Tanja Stachon [1], Arne Viestenz [1] , Nora Szentmáry [1,2], Berthold Seitz [1]

[1]Department of Ophthalmology, Saarland University Medical Center UKS, Homburg/Saar, Germany. [2] Klinik für Augenheilkunde, Semmelweis Universität, Budapest, Ungarn

Introduction: A lot of research progress on aniridia has been made on animal models. As we are working in a clinical environment transferring this knowledge to human patients is essential. There is still need to understand

the role of PAX6 in different human eye tissues, especially in limbal epithelial cells (LECs). Therefore, as a first step, we recently started to analyze the expression of 11 database provided transcript variants of PAX6. Our longterm aim is to compare patients' data to published animal models and find out reasons for high interindividual variability in clinical findings of aniridia patients. Variability is not exclusively coupled to different mutation types. We also start to establish a primary aniridia cell model.

Methods: Impression Cytology (IC) was used to isolate RNA from conjunctiva. For culture samples RNA was extracted directly from the cells. Following RNA isolation RT-PCR was performed, IC specimen showed hardly measurable RNA amount. RNA was used for RT-PCR. Human LECs were isolated from donor eye rims using collagenase digestion. Cultivation and siRNA transfection was carried out in KSFM using either HiPerFect® (Quiagen) or Lipofectamine® 2000 (Invitrogen). Fluorescent RNA-Oligo were used to compare transfection efficacy.

Results: All 11 PAX6 transcript variants could be found in cornea, conjunctiva, and LEC-culture from healthy donors. Most transcripts of PAX6 could be also found in oral mucosa tissue, and corneal keratocytes which we used as control tissue. We cannot exclude variations observed are only due to RNA amount and differences in quality as were only performing end point PCRs.
The transfection efficiency of LEC culture depends on transfection reagent and is much increased using Lipofectamine® 2000 compared of HiPerFect®.

Conclusions: Analysis of PAX6 expression patterns and probably other affected RNAs in Aniridia-patients is technically feasible. Retrieval of patient material need experts in ophthalmology department and is limited due to bad comparability between different patients and difficulties in sample retrieval. To compare changes in transcript levels of patients, we need to change to quantitative methods in future.
An Aniridia cell model, based on primary LECs, may help to overcome some limitations and reduce preliminary tests with rare and precious patient material. Nevertheless, moving away from animals is an important factor to correlate clinical findings with pathological mechanism in future.

Supported by COST action BM1302

CLINICAL OPHTHALMOLOGY: CORNEA

CORNEAL DIAGNOSTIC TOOLS FOR OCULAR SURFACE DISEASE

Gerd Geerling

University Eye Hospital Düsseldorf, Germany.

Aniridia can result in severe ocular surface disease. This presentation gives a short overview on various tools for detection and classification of ocular surface disease and their clinical usefulness.

BOSTON-KERATOPROSTHESIS: PRELIMINARY EXPERIENCES IN HIGH-RISK EYES FROM THE DEPARTMENT OF OPHTHALMOLOGY OF THE UNIVERSITY OF COLOGNE

Claus Cursiefen, Bachmann B, Schaub F.

Dept. of Ophthalmology, University of Cologne

BACKGROUND: Corneal transplantation in high-risk eyes remains a challenge. The Boston keratoprosthesis (B-KPro) is a final option for patients with end-stage corneal disease and a poor prognosis with conventional penetrating keratoplasty. In this article the results of the first 13 eyes that received a B-KPro type I at the Department of Ophthalmology, University of Cologne, Germany are reported and the usefulness of postoperative slit-lamp optical coherence tomography (SL-OCT) for control purposes is evaluated.

MATERIAL AND METHODS: All recipients of a B-KPro type I between September 2013 and May 2015 were included in the study. The feasibility of the operation, clinical outcomes, complications and revision surgery were investigated. The visualization of wound healing by SL-OCT was analyzed.

RESULTS: The age of the patients ranged from 26 to 92 years (mean 57.3 ± 20.9 years). In all 13 eyes from 12 patients (6 males and 6 females) dense corneal opacification with vascularization and sometimes also conjunctivalization was present. Preoperative visual acuity was reduced and

ranged from mere light perception up to a maximum of 1/35 eye chart. All 13 eyes could be supplied with a B-KPro type I without any intraoperative complications, in 6 eyes no significant postoperative complications occurred, whereas in 7 eyes various additional surgical interventions were required and 1 B-KPro could not be preserved. Postoperative visual acuity ranged from light perception to 20/32 and was significantly improved in 85 % of the treated eyes. The use of SL-OCT reproducibly allowed the postoperative assessment of stromal thinning.

CONCLUSION: The B-KPro provides the possibility of visual rehabilitation in high-risk eyes that could never be achieved without artificial cornea replacement. Despite higher complication rates this technique represents a significant progress in the surgical treatment of complex corneal pathologies. Regular and intensive postoperative controls are necessary to achieve good long-term results.

Excimer-PTK and Keratoplasty in Congenital Aniridia

Berthold Seitz, Elias Flockerzi, Tobias Hager, Nora Szentmáry, Barbara Käsmann-Kellner B, Arne Viestenz

German Aniridia Center, Department of Ophthalmology, Saarland University Medical Center UKS, Homburg/Saar, Germany

The conservative therapy of the often progressive limbal stem cell deficiency in congenital aniridia includes artificial tears containing unpreserved hyaluronic acid, gels, autologous serum and amniotic membrane transplantation. Only in case of significant reduction of visual acuity and/or recurrent epithelial defects limbal transplantation of various kinds and the Boston Keratoprothesis type I are supposed to be causal interventions.

However, in selected adult patients with minor conjunctivalisation and central Salzmann's nodules, pannectomy „in the correct layer", excimer laser phototherapeutic keratectomy (PTK) with masking fluid, 17 mm therapeutic contact lens and 100% autologous serum eye drops may be a minimally invasive therapeutic option.

As long as the endothelium is intact, a 14 mm deep lamellar corneoscleral graft, to co-transplant donor stem cells or even a 14 mm peripherally lamellar, centrally penetrating corneoscleral graft (saving the scleral spur!) may be a valid approach. In these patients, systemic immune suppression is

indispensable. In case of accompanying endothelial decompensation in adult patients with minor conjunctivalisation, we perform penetrating excimer laser keratoplasty (potentially as central homologous limbokeratoplasty, often with simultaneous open-sky cataract surgery as triple procedure in older patients), as a routine with simultaneous amniotic membrane transplantation (patch, to improve the limbal stem cell niche), temporary lateral tarsorrhaphy, 17 mm therapeutic contact lens and 100% autologous serum eye drops. As usual, no corneal transplantation is performed in case of uncontrolled intraocular pressure!

In conclusion, each microsurgical intervention in congenital aniridia shouldbe performed by the respective specialist and should be kept as minimally invasive as possible. In certain cases of "corneal opacities" in adulthood without major limbal stem cell deficiency, pannectomy and excimer laser PTK or penetrating excimer laser keratoplasty together with simultaneous amniotic membrane transplantation (as a patch), 17 mm therapeutic contact lens, lateral tarsorrhaphy and 100% autologous serum may result in a reasonable patient outcome.

- Seitz B, Langenbucher A, Kus MM, Küchle M, Naumann GOH: Nonmechanical corneal trephination with the excimer laser improves outcome after penetrating keratoplasty. Ophthalmology 1999; 106:1156-1165
- Seitz B, Das S, Sauer R, Hofmann-Rummelt C, Beckmann MW, Kruse F: Simultaneous amniotic membrane patch in high-risk keratoplasty. Cornea 2011; 30:269-272

Neuroscience, Low Vision Aspects, Quality of Life

Foveal morphology in PAX2 and early visual development in foveal hypoplasia

Irene Gottlob, Helena Lee, Mervyn Thomas

Department of Neuroscience, Psychology and Behaviour
The University of Leicester Ulverscroft Eye Unit, United Kingdom

PAX6 mutations result in pan-ocular phenotypes which include iris defects, ranging from subtle iris defects to subtotal aniridia. In addition to iris defects, foveal hypoplasia and nystagmus are common phenotypes associated with *PAX6* mutations. Using optical coherence tomography (OCT), examples of the

range of arrested retinal development associated with *PAX6* mutations are shown. Most of the patients with *PAX6* mutations have grade 1 – grade 3 foveal hypoplasia. Anterior segment OCT has potential to detect iris abnormalities in patients with *PAX6* mutations. Normally, the retina undergoes rapid development after birth. Using hand-held OCT suitable for infants and young children, we compared retinal development in healthy children to children with foveal hypoplasia. In foveal hypoplasia the retina continues to develop. In all cases with longitudinal follow-up, there was evidence of ongoing foveal development, with a reduction in foveal inner retinal layers thickness and elongation of the outer retinal layers with increasing age. We therefore, found that retinal development is not arrested in foveal hypoplasia, but is ongoing albeit at a reduced rate and magnitude in comparison to controls. This suggests that administration of therapy in early infancy and childhood, while there is still residual plasticity in the retina, may improve retinal development and optimize vision.

LOW VISION CARE IN ANIRIDIA PATIENTS: POTENTIAL AND CHALLENGES

Nhung Nguyen

Low Vision Rehabilitation Clinic, Center for Ophthalmology, University of Tuebingen, Germany

Background: Aniridia is a rare disorder with different ocular features: corneal dystrophy, glaucoma, cataract, macular hypoplasia, optic nerve hypoplasia. Typically, aniridia causes severe and progressive visual impairment.

Low Vision Care: In addition to glare caused by the iris defect, a marked reduction of visual function occurs at very young age due to underdevelopment of the macula and adjacent retina.
At first, the main problem is associated with near task such as reading and face recognition. However, with increasing decrease of the visual acuity, the mobility is limited increasingly. Additionally, many ocular complications arising during the lifetime may lead to total blindness.

Potential

1. **Glare**: Cutoff filters may improve contrast sensitivity and therefore lead to improved visual functions (contrast is enhanced and glare is reduced).

It is important to provide adequate illumination without glare (cold light source) and it is also helpful to vary the brightness according to the eye condition

2. **Near Task with regain reading ability by magnification of text and objects using optical and electronically low vision aid (LVA):** The spectrum of magnifying visual aids includes handheld magnifiers, stand magnifiers, simple high-plus spectacles, and telescopic spectacles. In patients with high magnification requirement (>6-fold) an electronic reading device should usually be used. Providing of LVA is most necessary for the school and at work.
3. **Orientation and Mobility:** For far distance viewing, handheld telescopes are very useful. Patients with new onset blindness or severe visual impairment should get orientation and mobility training, which allows maintaining travel independence with new orientation and mobility skills to compensate for reduced visual information
4. **Specific rehabilitation measures:** Besides continuously providing of low vision aids, all patients need further specific rehabilitation measure including early support, consulting for adequate school forms as well as for adequate occupation, supporting by special educators for visiting a mainstream school and supporting of workplace equipment under the consideration the individual visual impairment.

Challenges

1. It must be mentioned that there is no “universal” LVA for different visual Tasks.
   Each LVA is responsible for a certain situation (e.g. for reading, for middle distances, for the far distances). Therefore, providing of LVA must be done carefully and individually by trained persons
2. An effective treatment for many ocular complications still remains elusive leading to progressive, severe visual impairment and even to total blindness, so that individual and continuously low vision care is essential for the whole lifetime
3. The low vision ophthalmologist is usually the one, who follows the patients continuously, so that the low vision ophthalmologist should be aware of the potentially severity complication, in order to advising/referring patients to appropriate specialist for adequate treatment

Conclusions: Low Vision Care is a multidisciplinary process with the main aim to compensate patients´ visual deficits as extensively as possible helping patients having a personally independent, safe and productive life.

OCULAR SURFACE PROBLEMS IN ANIRIDIA – PATIENTS' EXPERIENCES

Barbara Käsmann-Kellner, Sidonie Droste zu Senden, Berthold Seitz

German Aniridia Center at the Department of Ophthalmology, Saarland University Medical Center UKS, Homburg/Saar, Germany

Background: Since the beginning of 2016, there are two new patient centered studies at the German Aniridia Center at the Saarland University Medical Center UKS, Homburg/Saar, Germany. The first study entails a cooperation with all departments and clinics of ophthalmology in Germany and aims at creating the German Aniridia Registry (ethics committee vote positive). The second is a trial for symptom relief in ocular surface disease, which is a very frequent and often impairing symptom in aniridia persons. At the moment, patients who responded to our questionnaire receive a newly developed eye drop consisting merely of semi-fluorinated alkane 1-perfluorohexyloctane (F6H8) which is a fluid with a very high capacity to cover surfaces without breaking up. We want to present the results of the questionnaire filled out by the patients concerning ocular surface disease. The results of the eye drop trial in aniridia will be presented at a later time. The study is performed with the support of Ursapharm (https://www.ursapharm.de/en/home/) who donates the medication (There are no financial interests involved for either author).

Patients: Of our 196 patients at the Aniridia Center Germany, we sent a questionnaire to all patients living in Germany (approx. 150). The questionnaire included the standardized form to evaluate the OSDI (Ocular Surface Disease Index), in addition, we asked what having aniridia means to our patients and how ocular surface problems impede with their daily life activities.
As the study only started 2 months ago, we cannot yet report on final numbers of participants. In addition, many parents of young children answered who at the moment do not yet have ocular surface problems.
We however noticed thankfully that many adult aniridia persons took great effort to fill out the questionnaire and seemed to be eager to write in their own words what aniridia and ocular surface disorder means to them in an individual and personal way.

Results: The reported feelings and attitudes concerning their aniridia surface problems varied greatly and did not always correlate to the examination results which we have of our patients. The evaluation of the OSDI, however, showed strong correlation to the individual corneal disease severity.

Surprisingly, many adults report that "aniridia" per se is not a major problem, but that they pinned their problems down either to low vision (more often) or to ocular surface discomfort and glare (up to now, less often than we had expected). Up to now, only one participant wrote about being disturbed by having "no eye colour" when engaged in social conversations. Many persons relate about photo-sensitivity, which is a problem directly related to age and the amount of ocular surface disease. Aniridia per se, without the corneal surface problems, does not cause such a severe photosensitivity. This can be seen in children and in the few aniridia adults who do not develop ocular surface problems – they report significantly less glare problems.
Some of the patients´ reactions were very blatant ("stupid disease") while others discriminated between different aspects of their life (private, social, education, profession) and of influencing parameters such as visual impairment, painful discomfort, aspect of appearance and dependence on others.

Conclusions: Apart from the evaluation of the OSDI before and after treatment with the novel eye formulation we wanted to offer an option for the patients to freely write their attitude and feelings on aniridia. Obviously, this was very well accepted and we thank our respondents for their honesty in answering our questions. In our opinion, such questionnaires concerning experiences with the disease and concerning quality of life questions should be offered more often to aniridia patients to be able to get to know their situations better and thus to be able to direct support in a more purposeful and individual way.

LIVING WITH ANIRIDIA – THE VIEW OF AFFECTED PERSONS

Rosa Sanchez de Vega (ES), Katie Atkinson (UK), Joeri Van den Bosch (BE)

Members of the The National Aniridia Organizations from Spain, United Kingdom, Belgium

People with aniridia have the potential to lead full and well-rounded lives but there are many different barriers they must overcome during their lifetime to achieve this, at school, at work, accessing the right health and social care and in everyday life. All of these challenges have an emotional and psychological impact and can influence a person's character. Aniridia is not only a congenital rare disorder, it is something which has a great impact on people, on their lives and their families. This is why, we think that it has to be managed in a

holistic way, taking into account a patient's individual circumstances, environment, lifestyle and priorities at that particular moment in time.

Receiving different and contradictory recommendations from different doctors about treatment, especially surgery, without a full understanding of the potential risks and benefits of each surgical procedure leaves the patient with a very difficult decision to make. They are not only considering how the outcome will affect the health of their eyes, they must also consider the impact on other aspects of their life such as their job, family life, mobility and ability to live independently. For many they must also consider how they will cover the financial costs of any surgery or treatment. This can lead to a lot of anxiety for the aniridia patient. Furthermore, the prospect of further sight loss (and in the worst cases total blindness) due to some of the other eye conditions commonly associated with aniridia leads to a lot of uncertainty for patients. Each time they lose some further sight they must learn to adapt to their new situation.

Patients are faced with the challenge, often without as much information as they would like, of deciding what treatment or surgery to have, by who, when, where and how it will be carried out. We must decide whether to choose a traditional treatment or try something new, perhaps better, but also less well tested. We must decide if the possible improvement in vision outweighs any potential risks. Ultimately we are thinking about whether this treatment will improve our quality of life, could the improvement in vision help us to tackle any of the challenges we face every day? Challenges at home such as cooking, cleaning and reading mail. Challenges outdoors such as not seeing steps and other obstacles, using public transport, reading maps and street signs. Dealing with photophobia and the inconvenience of having to wear sunglasses and / or a hat all the time, including how other people might perceive your appearance. Challenges at school with reading information on the blackboard or in books. Challenges in finding an employer who is willing to give us a chance, who can provide any adaptations we need and will be understanding if we need to take time off for treatment. Challenges of forming friendships and romantic relationships when we may not recognize people's faces or respond to their facial expressions. Challenges to having fun such as seeing the screen at the cinema or playing sport, and of course the challenge of social discrimination. A change in our vision for the better or worse can change all of these things and so patients have a lot to consider when deciding on the benefits and risks of any treatment.

All of these things affect our quality of life, as do questions of genetics such as, can we have the option to have children without aniridia? What is our individual genetic anomaly and could it cause problems outside of the eye, so called "Aniridia Syndrome"?

All this leads, from the patients' point of view, to the need for more research on this rare condition and more accurate agreement on standardized information about possible treatment and its benefits, risks and side-effects. This information could be drafted into European Aniridia Guidelines.
We believe that doctors should look at the whole picture of a patient's life, not just how the appearance of their eye, when thinking about treatment and surgery and also listen to what the patient wants and find out what is most important to the patient at this point in their life.

We would also like to see doctors collaborate more as an expert research network, to exchange valuable information about the different treatments. By gathering as much (anonymous) data together as possible we can move forward and make a real difference for people with aniridia.
In this talk three aniridia patients will describe some of their own personal experiences, the challenges and difficult decisions they have faced which have led us to share this common point of view.

For your notes

SUNDAY AUGUST 28TH, 2016

WAGR Syndrome & Wilms Tumor, metabolic alterations in PAX6 haploinsufficiency

WAGR syndrome: Guidelines for Clinical Management

Kelly Trout

President, International WAGR Syndrome Association
www.wagr.org

INTERNATIONAL WAGR SYNDROME ASSOCIATION

WAGR syndrome is a rare genetic disorder caused by a deletion on the distal band of 11p13. WAGR is an acronym for the classical clinical features of the syndrome: Wilms tumor, Aniridia, Genitourinary abnormalities, and a Range of developmental delay. In recent years, new genotypic and phenotypic variations beyond the classic WAGR presentation have been identified. This presentation will explore these newly identified variations and their implications for the diagnosis, evaluation, treatment, and surveillance of patients with WAGR syndrome.

Role of brain-derived neurotrophic fact in obesity, intellectual disability, and impaired nociception in patients with WAGR syndrome

Joan C Han

Department of Pediatrics, Le Bonheur Children's Hospital, Memphis, TN, USA

Rare genetic disorders that cause *BDNF* haploinsufficiency, such as WAGR syndrome, 11p deletion, and 11p inversion, serve as models for understanding the role of BDNF in human energy balance and neurocognition. Patients with *BDNF* haploinsufficiency or inactivating mutations of the BDNF receptor exhibit hyperphagia, childhood-onset obesity, intellectual disability, and impaired nociception. In the general population, common variants of *BDNF* that affect *BDNF* gene expression or BDNF protein processing have also been associated with modest alterations in energy balance and cognitive functioning.
Thus, variable degrees of BDNF insufficiency appear to contribute to a spectrum of excess weight gain and cognitive impairment that ranges in phenotypic severity. In this modern era of precision medicine, genotype-specific therapies aimed at increasing BDNF signaling in patients with rare and common disorders associated with BDNF insufficiency could serve as useful approaches for treating obesity and neurodevelopmental disorders (Han JC. Prog Mol Biol Transl Sci. 2016; 140:75-95).

Wilms Tumor: Treatment Protocols and Quality of Life

Norbert Graf

Department of Paediatric Oncology/Hematology, Saarland University Hospital Homburg, Homburg/Saar, Germany

Wilms tumour is the most common malignant renal tumour in children. Dramatic improvements in survival have occurred over the last 40 years. Today treatments are based on several multicentre trials and studies conducted by the SIOP in Europe and COG in North America. Main objectives of these trials and studies are to treat patients according to well-defined risk groups in order to achieve highest cure rates, to decrease the frequency and

intensity of acute and late toxicities and to minimize the cost of therapy. In that way the SIOP trials and studies largely focus on the issue of preoperative therapy. The concept of neoadjuvant chemotherapy plays an important role in the treatment for most paediatric solid tumours today. The complete surgical removal of a shrunken tumour is facilitated, mutilation caused by surgical procedures is minimized or avoided and micrometastases, not visible at diagnosis, are treated as early as possible. Besides that, response to treatment can be measured individually by tumour volume reduction and / or percentage of therapy induced necrosis in the histological specimen.

The International Society of Paediatric Oncology (SIOP) enrolled children with Wilms tumour into 7 studies up to now (SIOP 1, SIOP 2, SIOP 5, SIOP 6, SIOP 9, SIOP 93-01, SIOP 2001). Graf et al give a review of these studies[1]. Today more than 10.000 patients with a kidney tumour are enrolled in the SIOP studies and trials.

Commonly occurring somatic gene mutations in Wilms' tumor are those of WT1, WTX, CTNNB1 and TP53. Although they may occur single or in combination they are only involved in one third of tumors. *IGF2* has been mapped to the short arm of chromosome 11p15, which also harbors WT susceptible genes, like *WT1*. Patients heterozygous for WT1 germline mutations are predisposed to WT. The WAGR syndrome is caused by a complete deletion of one copy of WT1 and the adjacent aniridia gene, PAX6 on chromosome 11p13. In patients with aniridia this information helps to identify those patients, who are at risk for developing Wilms' tumour, by screening them for the combined deletion of WT1 and PAX6. WT1 is also involved in the Denys-Drash syndrome (glomerulosclerosis, Wilms' tumour, and ambiguous genitalia) caused by dominant-negative germ line point mutations. A similar constitutional WT1 splice-site mutation underlies the Frasier syndrome (intersex, nephropathy and gonadal tumors). It is of interest that in only 5% of Wilms' tumors a constitutional, and in further 10% a sporadic, WT1 mutation can be found. In those with germ line mutations bilateral Wilms' tumors are more frequent. In sporadic Wilms tumors the driving somatic genetic aberrations need to be further unraveled.

After preoperative chemotherapy the WT needs to be operated and postoperative treatment mainly depends on histology, local stage and response to preoperative treatment.

Today more than 90 % of patients with Wilms tumour can be cured[2,3]. Clinical trials for Wilms tumour continue to seek risk factors for further stratifying and individualizing treatment. This will improve the cure rates for high risk patients by intensifying therapy and the quality of life for children with more

favourable prognosis by lowering therapy to the minimum required, both leading to more personalized medicine.

[1] Graf N, Tournade MF, de Kraker J: The Role of Preoperative Chemotherapy in the Management of Wilms Tumor - The SIOP Studies. Urologic Clinics of North America, 27:443-454, 2000
[2] de Kraker J, Graf N et al.: Reduction of postoperative chemotherapy in children with stage I intermediate risk and anaplasia Wilms'Tumour. The SIOP 93-01 randomised trial. Lancet 364:1229-1235, 2004
[3] Pritchard-Jones K, Bergeron C, ... and Graf N on behalf of the SIOP Renal Tumor Study Group: Doxorubicin omission from the treatment of stage II/III, intermediate risk histology Wilms tumour: results of the SIOP WT 2001 randomised trial. Lancet 386:1156-1164, 2015

OPHTHALMOLOGICAL CHALLENGES IN WAGR PATIENTS

[1]Barbara Käsmann-Kellner, [1]Arne Viestenz, [2]Norbert Graf, [2]Rhoikos Furtwängler

[1]German Aniridia Center at the Department of Ophthalmology, Saarland University Medical Center UKS, Homburg/Saar, Germany
[2]Department of Paediatric Oncology, Saarland University Medical Center UKS, Homburg/Saar, Germany

Background: WAGR syndrome is a disorder that affects many body systems and is named for its main features: **W**ilms tumor, **a**nirida, **g**enitourinary anomalies, and intellectual disability (formerly referred to as mental **r**etardation). When WAGR syndrome includes childhood-onset **o**besity, it is often referred to as **WAGRO** syndrome. In both types, there may be behavioural problems.
WAGR syndrome is often described as a contiguous gene deletion syndrome (11p deletion syndrome) because it results from the loss of several neighboring genes. The severity of the diseas manifestation depends on the length of the deletion and the included genes.
The prevalence of WAGR syndrome ranges from 1 in 500,000 to one million individuals. Approximately 7 in 1,000 cases of Wilms tumor can be attributed to WAGR syndrome. People with WAGR syndrome have a 45 to 60 percent chance of developing Wilms tumor of the kidney. This type of cancer is most often diagnosed in children but is sometimes seen in adults. Abnormalities of the genitalia and urinary tract are seen more frequently in males with WAGR syndrome than in affected females. The most common genitourinary anomaly in affected males is undescended testes (cryptorchidism).

Patients: As of 2016, we regularily see 14 persons with WAGR syndrome at the German Aniridia Center. In addition, the first author has examined

another 6 patients from Russia once at Moscow. 5 of 20 patients have no intellectual deficits, two have passed University studies, two others are learning Braille. Out of 20 patients, 13 had Wilms tumor in childhood and had been treated by one or more surgeries and chemotherapies. The 7 children without WT show an age range from 2 to 7 years. One girl aged 7 who does not have WT had a growth of unclear dignity in her right eye which was enucleated. One boy, now aged 2, shows precancerous lesions in renal biopsies. Two other boys and one girl are still young and might develop WT later, one boy has been lost to follow-up in the past 3 years.

Results: All our patients have aniridia, one of them accompanied by clinical features of Peters syndrome (congenital corneal opacification, complete aniridia). All 20 patients have been molecular genetically analysed and confirmed as WAGR microdeletion 11p syndrome. The total of 20 patients (age 2 to 39) all show severe manifestations of aniridia-related problems, especially concerning the corneal complications, secondary glaucoma and high refractive anomalies. This applies as well to the very young patients. Therefore, many young WAGR patients need intraocular surgery and postoperative monitoring (cataract and glaucoma surgery). There are three WAGR patients with pathological myopia and consecutive retinal detachment in one or both eyes. When comparing the WAGR patients to our aniridia patients with confirmed PAX6 mutations (n = 107 of a total of 193 patients), the complications of aniridia in WAGR patients appear more early in life and tend to be more severe.
Another common feature of WAGR syndrome is intellectual disability. Affected individuals often have difficulty processing, learning, and properly responding to information. Some individuals with WAGR syndrome also have psychiatric or behavioural problems including depression, anxiety, attention deficit hyperactivity disorder (ADHD), obsessive-compulsive disorder (OCD), or behavioural problems of the autism spectrum disorder affecting communication and social interaction.

The examinations of WAGR patients with mental deficits and behavioural problems is much more challenging than in non WAGR aniridic children. Aggressive actions towards the examiner are not a rarity. Examinations and treatment decision findings are often prolonged by the inability of the children to co-operate, especially concerning machine-related exams such as the slit lamp or measuring the intraocular pressure. Visual acuity testing is much more difficult as well, as some patients will not have the attention span to fixate objects in a distance of 5m. Physicians need much more time and need ideas to distract the young patients while trying to obtain examination results. In cases where cooperation is insufficient and findings doubtful, there

is no other option than performing an exam under general anaesthesia. This is always well accepted by the parents who estimate if the physician takes efforts to examine their children.

In addition, a good cooperation with the Paediatric Oncology Unit is extremely beneficial to be able to check the kidneys at short notice and to save the patients longer travels.

Conclusions: WAGR children show the same aniridia-related complications as patients with PAX6 related aniridia. Unfortunately, they tend to appear earlier and more severe than in the average of PAX6 aniridia patients. Therefore, thorough and exact examinations are mandatory to diagnose complications as soon as possible – this applies especially to secondary glaucoma which can not be seen (as opposed to corneal complications and cataract) by lighting the anterior segments of the eye. Due to the intellectual and behavioural problems the examinations and diagnosis of complications is very challenging, but needs to be performed with utmost efforts, as these children, who have mental and motor deficits will suffer even more than mentally healthy children if their visual impairment turns to blindness.

SLEEP DISTURBANCES IN PAX6 HAPLOINSUFFICIENCY

Joan C Han

Department of Pediatrics, Le Bonheur Children's Hospital, Memphis, TN, USA

Paired box 6 (PAX6) appears to play an important role in the development of the pineal, the primary source of the circadian regulating hormone, melatonin. We examined pineal volume, melatonin secretion, and sleep disturbance in 37 patients with *PAX6+/-* (age 15.3±9.9 years) and 17 healthy controls (16.0±7.2 years). Pineal volume was evaluated by magnetic resonance imaging (MRI). Diurnal serum cortisol, serum melatonin, and urine 6-sulfatoxymelatonin (6SM) concentrations were measured by enzyme-linked immunosorbent assay. The Child Sleep Habits Questionnaire (CSHQ) was administered for participants <13y. Pineal volume was 5-fold lower in *PAX6+/-* vs. controls (mean±SD: 25±15 vs. 129±50 µL, $p<0.001$). Midnight serum cortisol was similar in *PAX6+/-* vs. controls ($p=0.14$). Midnight serum melatonin was >2-fold lower in *PAX6+/-* vs. controls (median [25th-75th]: 28 [22-42] vs. 71 [46-88] pg/mL, $p<0.001$). First morning void urinary 6SM was 4-fold lower in *PAX6+/-* vs. controls (11 [6-26] vs. 45 [34-61] ng/mgCr, $p=0.001$). CSHQ score was higher in *PAX6+/-* vs. controls (48±6 vs. 41±5, $p=0.03$). Our

findings suggest that *PAX6+/-* is associated with smaller pineal size, lower melatonin secretion, and greater parental report of sleep disturbances in children. Further studies are needed to explore the potential use of melatonin replacement for improving sleep quality in patients with *PAX6+/-* (Hanish AE et al. J Sleep Res. Epub ahead of print).

CLINICAL OPHTHALMOLOGY: CATARACT & GLAUCOMA

CATARACT IN ANIRIDIC PATIENTS: SPECIAL FEATURES AND PERSONAL EXPERIENCE

Dominique Bremond-Gignac[1,2]

[1] Head of Ophthalmology Department, University Hospital Necker-Enfants malades, APHP, Paris, France
[2] CNRS Unit FR3636, Paris V University, Paris, France

Congenital aniridia is a rare genetic ocular disorder affecting anterior and posterior segment of the eye. Many clinical forms of the disease with major visual impairment may be observed. Ocular clinical signs in aniridia may associate glaucoma, limbal insufficiency leading to keratopathy, cataract, ptosis, foveal aplasia, optic nerve hypoplasia or a microphthalmia. The cataract in aniridia must be identified with its specificities in order to adjust the treatment according with other ocular signs and complications of the disease. The cataract formation in aniridic patients was reported by the age of 20 year-old from 50% to 85%.

In aniridia, cataract is usually reduced in infancy to mild opacities or partial lens opacification however in some cases congenital cataract is complete at birth. A retrospective study of 105 patients with congenital aniridia is presented. Cataract is evaluated in its presentation and its evolution. When visual acuity becomes low, time of cataract surgery must be discussed. Some specificities of the lens and cataract surgery in aniridic patients are described. Anterior fibrosis syndrome is a severe complication of cataract surgery. Increased ocular pressure, ocular surface impairment and retinal detachment may be observed as secondary complications. Cataract in aniridia patients commonly is well tolerated and not the main cause of low vision. If the visual

acuity is compatible with foveal aplasia and ocular surface impairment, cataract surgery must be differed until the lens opacification demonstrates to be responsible of the visual impairment. Cataract surgery with or without intraocular lens with or without iris replacement must be discussed to evaluate the benefice/risk. An improved clinical management of the cataract allows a better overall care of aniridic patients.

EVALUATION OF PROVIDED INDICATIONS FOR AN ARTIFICIAL IRIS IMPLANTATION AND RISKS OF ARTIFICIAL IRIS IMPLANTATION IN CASE OF CONGENITAL ANIRIDIA

Vadim Bondar

Department of Ophthalmology, FANTASY Detskaya Klinika (Paediatric Hospital), Moscow, Russia

Background: Aniridia is a congenital condition whose most significant symptom is absence of the iris. The indications provided for the implantation of an artificial iris are widely known. They are: increased glare sensitivity (photophopbia), blurred vision, cosmetical effect. In most cases the decision to have surgery is made by patients' parents and doctors. Numerous researches show that this type of surgery really results in a decrease of light sensitivity and gives an adequate cosmetic effect, but there is no information about the personal perception of the necessity of these changes by the patients. Was this cosmetic effect really that important for the child? Was light sensitivity that hard to endure? It is also important to evaluate the long-term effects of the implantation of an artificial iris.

In our clinic we investigated how significant these indications were for patients. As researchers noticed - photophobia and cosmetic defect are the most important indications for artificial iris implantation, but all patients have different levels of photophobia and nobody seems to pay attention to this difference. It is a very important question because the decision about the necessity of a surgery is made not by patients (they are too young in most cases) but by doctors and parents.

Differences in level of photophobia were evaluated and compared in different groups of patients with congenital aniridia depending on the presence of another ocular pathology (optic nerve and foveal hypoplasia).

We have estimated the results of the performed artificial iris implantations in a long-term period (the results were taken from published papers and from our own observations).

Methods: Photophobia and the way patients feel about the absence of an iris (whether they find it a significant cosmetic defect or not) has been investigated through a survey. The survey has been conducted among patients older than 5. The children were asked how photophobia and the absence of an iris affect their life (38 patients). We have also estimated the correlation between photophobia and other ocular changes such as optic nerve hypoplasia and foveal hypoplasia. Doubtful cases of optic nerve hypoplasia were regarded as the absence of optic nerve hypoplasia. For estimating the structure of the possible complications among patients having gone through an artificial iris implantation we have used the data received from the observation of the patients of our own (six eyes) and the clinical data review (24 eyes).

Results: Only 2 patients have reported that they have a significant photophobia and they always need tinted glasses outdoors. 9 patients said that they didn't have a significant level of photophobia and in most cases they wear dark glasses because their doctor said that they needed them. 25 patients have slight photophobia only outdoors. 3 of the patients said that they had no photophobia at all. None of the interviewed patients thinks that the absence of an iris is a cosmetic defect worth lots of worries.

High and mild glare sensitivity is in most cases correlated with optic disc hypoplasia. 2 patients with high glare sensitivity have a noticeable nerve hypoplasia.

The outcomes of the artificial iris implantation are estimated according to clinical reviews (16 cases) and own observations (3 cases).
The longest period of observing a patient after an artificial iris transplantation is ten years. Judging by the clinical reviews and own observations the most frequent complications after the surgery have been a significant ocular hypertension and keratopathy aggravation. Most researches don't take into consideration long-term changes.

GLAUCOMA AND CATARACT SURGERY IN ANIRIDIA WITH AN EMPHASIS ON GLAUCOMA TUBE SURGERY

Peter A. Netland

Vernah Scott Moyston Professor and Chair, University of Virginia, Department of Ophthalmology, Charlottesville, Virginia, USA

Aniridia is a panocular condition, which is frequently associated with cataracts and glaucoma. Lens abnormalities are a common cause of reversible loss of vision in aniridia patients. In our patients, the average age of cataract diagnosis and surgery was 9 years and 28 years, respectively. Although aniridia fibrosis syndrome (AFS) is a concern, patients usually experience good surgical outcomes after cataract surgery in aniridia. Aniridic glaucoma usually develops during childhood, and may cause of irreversible vision loss. In our study of Aniridia Foundation International (AFI) members, approximately half of the subjects developed glaucoma, with glaucoma diagnosis at average age 13.6 years and median age 8.5 years. The majority of patients were treated surgically for glaucoma. Average central corneal thickness is increased in aniridia, which may be a consideration for assessment of intraocular pressure. The majority of patients with aniridia and glaucoma are treated surgically. Although surgical procedures vary, clinicians often use glaucoma drainage implants to treat aniridic glaucoma. Regular monitoring during childhood, with prompt recognition of elevated intraocular pressure and effective management, may prevent vision loss due to glaucoma in aniridia.

SECONDARY GLAUCOMA IN CONGENITAL ANIRIDIA: ANATOMY OF THE ANTERIOR CHAMBER ANGLE AND CONSEQUENCES FOR TRABECULOTOMY / CYCLOPHOTOCOAGULATION

Arne Viestenz, Eva Deland, Berthold Seitz, Barbara Käsmann-Kellner

German Aniridia Center at the Department of Ophthalmology, Saarland University Medical Center UKS, Homburg/Saar, Germany

Background: Intraocular pressure (IOP) lowering surgery in congenital aniridia may be complicated by dysgenesis of the anterior chamber angle, iris and lens.

Methods: The anterior segment of 17 patients with congenital aniridia was investigated under general anaesthesia with ultrasound biomicroscopy (UBM). The structures of anterior segment were evaluated: distance of ciliary

body processes from the anterior chamber angle and positioning of Schlemm´s canal. A surgical plan was created based on these data.

Results: Schlemm´s canal was detected in 21 of 23 examined eyes. The mean distance from anterior chamber angle was 1.3 +/- 0.4 mm (range: 0.5 to 2.1 mm). This resulted in a more differentiated kind of UBM-based trabeculotomy. Using diaphanoscopy and UBM, the ciliary body was detected and coagulated with a diode laser probe (810 nm). The IOP was reduced in 16 patients sufficiently.

Conclusions: The initial UBM-examination is essential in eyes with congenital aniridia scheduled for cyclophotocoagulation or trabeculotomy.

Concluding Session with question time for listening patients & Farewell

Summaries of the scientific talks (in German) Options to ask questions to the attendant clinical and scientific researcher

Zusammenfassungen der wesentlichen Ergebnisse der wissenschaftlichen Vorträge Möglichkeiten, den anwesenden Klinikern und Laborforschern Fragen zu stellen

Barbara Käsmann-Kellner, other speakers to be announced

ANIRIDIA AND SOCCER – TRIBUTE & THANK YOU TO 1. FC UNION BERLIN, SOCCER CLUB, 2ND BUNDESLIGA

Barbara Käsmann-Kellner[1,3], Denice Toews-Hennig[2,3]

[1]German Aniridia Center at the Department of Ophthalmology, Saarland University Medical Center UKS, Homburg/Saar, Germany. [2]President, Aniridie-WAGR Support Group Germany, Michelau, Germany. [3]Member of 1. FC Union Berlin

The story between Denice Toews-Hennig, Aniridie-WAGR Support Group Germany, Prof. Dr. Barbara Käsmann-Kellner at the University of Saarland and the 1. FC Union Berlin Soccer Club began in the beginning of the year 2013, when a new player of the Berlin soccer team became father of a sweet little boy with aniridia. Having just moved from his former Soccer Club at Aalen in Southern Germany to the Capital to join the famous Berlin soccer club (https://www.fc-union-berlin.de), all fans looked at the newcomer Martin Dausch (who, as all his team colleagues, soon was called "Fußballgott" – Soccer God) and his lovely young wife Lisa, who several weeks ago had given birth to a healthy boy called Luca with aniridia.

Interest not only in the new team player rose, but as well in the wellbeing and future of his little son Luca. Many thousand soccer fans encountered the word "aniridia" for the first time and learned about congenital visual impairment, nystagmus, possible complications and more.

In late spring of that year, one of the fans, Sven Köhler (who actually is the Head of our technical team at this Conference, providing loudspeakers, beamer, translators – http://highlight-berlin.de) had the idea to arrange a sponsoring event at the football stadium of the 1. FC Union Berlin. He named it "Gemeinsam SEHEN – UNION leben" (SEEING together – living in UNION) and another fan quickly created a logo for the action.

Sven Köhler organized a huge "paint-in" at the Union stadium, inviting all fans and their children to paint eye or vision related images. Sunday August 18th, 2013, the stadium opened the doors for hundreds of Union fans and their families – everyone, including the professional players of the dub, painted, talked about aniridia and – of course – soccer. The next day was a game of the 1. FC Union at home, and all sides of the stadium were filled with paintings instead of advertise-ments.

The next step, of course, was the selling of the pictures which took place – all organized by Sven Köhler as well – during the following games, during a boat festival on the River Spree and during many more occasions. Thus, a sum of over € 18.000 could be collected and was officially given to the "Research Account" of the Aniridie-WAGR support group.

Denice Toews-Hennig and myself had the honour to receive the cheque by Sven Köhler, the press relations officer of the 1. FC Union Christian Arbeit and by Martin Dausch at the VIP Lounge of the stadium in the end of September 2013. All these actions were accompanied by newspaper reports and short TV reports and helped to make aniridia known in Germany to a much higher degree.

By these actions – Martin speaking openly about the rare eye disease of his son, and Sven Köhler´s brilliant "Paint & Pay" idea together with the efforts of so many fans of Union Berlin made it possible to establish the Research Fund at Aniridie-WAGR support group.

There were more great things to follow – for example the production of a new song for Union, written and sung by Roland Krispin, who donated the revenues to Aniridie-WAGR e.V., and other events in Berlin pro bono for aniridia research.

With this short story and some pictures of the events we want to cordially thank Sven Köhler, Martin Dausch and his family and parents and especially the unbelievable fans of 1. FC Union Berlin for being so actively engaged in all actions and for helping in a selfless way to make aniridia research a reality. Needless to say – since September 2013 Denice and myself are members of 1. FC Union. A soccer club membership at least I had never thought would be thinkable for me – but I just love these positively cuckoo fans.

Eisernen Dank!!

CONCLUDING REMARKS AND THANK YOU

Denice Toews-Hennig, President **A**niridie-**W**AGR **S**upport Group **AWS** Germany

Barbara Käsmann-Kellner, GER, German Aniridia Center, Medical Advisor **AWS** Germany

New President of Aniridia Europe **AE,** Country to be announced

Gaelle Jouanjan, Geniris, and Dominique Bremond-Gignac, France:

- Information on European Reference Network **ERN EYE / RED Rare Eye Disease**
- Announcement of the **4th European Aniridia Conference 2018, Paris, France**

POSTER ABSTRACTS & INFORMATION ON ANIRIDIA AND SPORTS

REGENERATION OF THE ANTERIOR CORNEA THROUGH A TRANSPLANTATION OF CULTIVATED LIMBAL EPITHELIAL STEM CELLS: EARLY RESULTS OF A PHASE II CLINICAL TRIAL

Behaegel Josephine[1,3], Ni Dhubhghaill S[2], Koppen C[2], Leysen I[2], Melsbach E[1], Haagdorens E[1], TenTusscher M[3], Tassignon MJ[2], Zakaria N[1,2]

[1] Centre for Cell Therapy and Regenerative Medicine UZA, Antwerp, Belgium. [2] Dept of Ophthalmology, UZA, Antwerp, Belgium. [3] Dept of Ophthalmology, UZB, Brussels, Belgium. [4] Dept of Ophthalmology, UZB, Ghent, Belgium.

Introduction: Limbal stem cell deficiency (LSCD) results from a loss of corneal epithelial stem cells and a breakdown of the limbal barrier, due to acquired or congenital diseases such as aniridia. This results in vascular and conjunctival overgrowth, corneal opacification, pain, photophobia and a drop in visual acuity. These corneas are at high risk for donor cornea rejection and regarded as an orphan pathology. Ex vivo cultivated limbal stem cell grafts aim to restore the limbal barrier and reconstruct the ocular surface, improving rates of subsequent corneal graft survival.
We report the early results of our phase II multicenter trial, in which we transplant non-xenogenic, bioengineered, composite grafts of cultured limbal epithelial cells on standardized amniotic membranes in patients with LSCD.

Methods: Thus far a total of 11 patients with total limbal stem cell deficiency have received either autologous (n=9) or allogenic (n=2) stem cell grafts.
The limbo-amnion grafts were generated by cultivating limbal epithelial stem cells from the contralateral eye or from an HLA-matched living related donor eye on a standardized amniotic membrane. The cells were cultured for a period of 2 weeks in a xenogenic-free culture medium and the composite graft was transplanted with a standardized 'no touch' surgical technique.

Results: The mean follow-up so far is 22 weeks (range 10-36 weeks). Seven of the 11 (64%) patients experienced a functional improvement, including

reduced pain, photophobia and/or an improvement in visual acuity. Two (18%) patients encountered epithelium closure problems and/or revascularization in the early post-operative course and therefore will be considered to receive a second stem cell transplantation.

Conclusions: Transplantation of ex vivo cultivated limbal stem cells through this standardized culture system and surgical approach can offer corneal rehabilitation in both unilateral and bilateral stem cell deficient eyes. So far the grafts were well tolerated and offered a functional improvement. If vascularization or epithelial defects recur, a second transplantation can be offered.

LONG TERM FOLLOW-UP OF PATIENTS WITH CONGENITAL ANIRIDIA

Ulla Edén[1], Neil Lagali[1], Ruth Riise[2], Kristina Tornquist[3], Per Fagerholm[1]

[1]Department of Ophthalmology, Institute for Clinical and Experimental Medicine, Faculty of Health Sciences, Linköping University, 581 83 Linköping, Sweden
[2]Department of Ophthalmology, Innland Hospital, Elverum, Norway
[3]Department of Ophthalmology, Lund University, Sweden

Purpose: To investigate the progression of congenital aniridia over time and to determine whether different treatments tend to improve or worsen the condition.

Material: Out of 124 congenital aniridia patients initially examined in 2004 - 2005 (79 in Sweden and 45 in Norway), 16 patients from Sweden were reexamined after 4 years and 16 from Norway after 8 years.

Methods: Ophthalmic examinations consisted of best spectacle-corrected visual acuity (BSCVA), corneal sensitivity (different methods in the first and second examination), tear quantity by the Schirmer I test and quality (BUT). Slit lamp examination was performed and digital photographs were used to document the phenotypic appearance.

Results: Visual acuity remained generally stable between successive examinations.

Fifteen eyes had gone through cataract surgery before the first examination and another 6 eyes between the first and second examination. Two of the eyes had decreased in BSCVA, 3 were equal and 1 eye improved by 2 lines. Twenty-two eyes had glaucoma and no new eyes with glaucoma were found at the second examination. Nine eyes had surgery for glaucoma, 3 eyes between the examinations.
Out of 54 eyes examined 45 eyes had aniridia-related keratopathy (AAK) to some extent. Of the 52 eyes re-examined, only 2 eyes still did not have visible AAK.

Conclusion: Visual acuity remained generally stable between successive examinations. Cataract surgery did not appear to improve vision, however only 6 patients in the present cohort had complete cataract data. Out of these just one eye improved by 2 lines of vision. By contrast, almost all eyes except two exhibited a visible aniridia-related keratopathy (AAK). It therefore appears that treatments should focus on improving AAK to enable better visual outcomes to be achieved.

ANIRIDIA: SPORTS AND DAILY LIFE

Matteo Castelnuovo[1], Gianmaria Dal Maistro[2], Barbara Poli[3]

[1]Journalist and Vice President of Aniridia Italiana, Milano, Italy
[2]Paralympic ski champion (9 olympic medals), Reference Person for sport of Aniridia Italiana, Torino, Italy
[3]Librarian, Vice President of Aniridia Europe, Delegate of Aniridia Italiana for Aniridia Europe, Venice, Italy

This project stems from the idea that playing sports together means also creating connections and human relations based on trust and dialogue. Each of the stories presented within the booklet *Sport and visual impairment: theory and practice*, in fact, is a key element of what we would like to convey with our activities for patients and all people who want to get in touch with us.

The concept on which we base the activities of the corner "Aniridia: sports and daily life" will be a mix of experience and new knowledge promoted through the dialogue and the contribution of anyone who wants to try to learn about what it means or what may represent a new way to face the

relationship that every person affected by aniridia can have every day with the challenges he/she experiences.

From the best practices on mobility to the good usage of technology, from dealing with people to the management of pain, from the desire for overcoming to the need of physical as well as psychological balance, we will try to develop a cognitive and informative process to make possible for people to understand the importance of avoiding to isolate themselves, and of trying instead to make themselves autonomous as much as they can, finding the strength and the desire to refer constantly to other people to take positive and proactive cues from them.

This is our philosophy of life: no one can make it alone, but by building a network of contacts, friends and acquaintances, everyone can always find new answers to concrete issues, such as degeneration of vision, increase of pain or fear for the future.

Finally, we would like to provide, as far as possible, to the parents of affected children and teens attending the Conference, the occasion to create a constructive dialogue in which patients aged between 30 and 40, as we are, can offer them a highly valuable and forward-looking perspective of the opportunities which may be taken also by people affected by this rare disease which, despite producing substantial limitations in the visual function, cannot preclude in any way the possibility to live with satisfaction every moment of the day through an approach that aims at making serenity and completeness possible for any person.

CONTACT INFORMATIONS OF THE FIRST SPEAKERS, SORTED ALPHABETICALLY

Akerli

Asbjørn Akerlie, President of Aniridia Europe 2014 – 2016
Spångbergveien 9A, 0853 Oslo, Norway akerlie@aniridia.eu

Aniridie-WAGR Support Group e.V.; Denice Toews-Hennig, President
Georg-Friedrich-Händel-Str. 7, 96247 Michelau, Germany info@aniridie-wagr.de
www.aniridie-wagr.de

Atkinson

Katie Atkinson PhD, Chairperson of ANUK Aniridia Network UK, Sheffield, United Kingdom katie.atkinson@aniridia.org.uk

Behagel

Dr. Josephine Behagel, Centre for Cell Therapy and Regenerative Medicine UZA, Antwerp, Belgium; Dept of Ophthalmology, UZB, Brussels, Belgium.
josephine.behaegel@uzbrussel.be

Bolz

Prof. Dr. med. Hanno J. Bolz, Deputy Medical Director, Center for Human Genetics, Bioscientia, Konrad-Adenauer-Str. 17, 55218 Ingelheim, GERMANY
hanno.bolz@bioscientia.de

Bremond-Gignac

Prof. Dominique BREMOND-GIGNAC, MD, PhD, Head of Ophthalmology Department, University Hospital Necker-Enfants malades, APHP, 149 rue de Sèvres, 75015 Paris, France dominique.bremond@aphp.fr

Bondar

Dr. Vadim Bondar, Department of Ophthalmology, FANTASY Detskaya Klinika (Paediatric Hospital), Moscow, Russia 5071689@gmail.com

Castelnuovo

Matteo Castelnuovo, Journalist at Regione Lombardia, Journalist bei COOLMag.it, , Vice President of Aniridia Italiana, Milano, Italy. Matteo.castelnuovo@aniridia.it

Supported by COST action BM1302

Connon

Prof. Dr. Che J Connon, PhD, Professor of Tissue Engineering, Institute of Genetic Medicine, Newcastle University, International Centre for Life, Central Parkway, Newcastle upon Tyne NE1 3BZ United Kingdom che.connon@ncl.ac.uk

Cursiefen

Prof. Dr. med. Claus Cursiefen, FEBO Geschäftsführender Direktor des Zentrums für Augenheilkunde Universität zu Köln Kerpenerstr. 62 50924 Köln; Germany, Sprecher, DFG Forschergruppe 2240 www.for2240.de claus.cursiefen@uk-koeln.de

Dal Maistro

Gianmaria Dal Maistro, iOS Developer bei Ennova Group; Paralympicski champion (9 olympic medals), Reference Person for sport of Aniridia Italiana, Torino, Italy www.whiteworld.it

Eden

Dr. Ulla Eden MD PhD, Department of Ophthalmology, Institute for Clinical and Experimental Medicine, Faculty of Health Sciences, Linköping University, 581 83 Linköping, Sweden ulla.eden@gmail.com

Geerling

Prof. Dr. G. Geerling, Augenklinik, Universitätsklinikum Düsseldorf, Moorenstr. 5, 40225 Düsseldorf geerling@med.uni-duesseldorf.de

Gottlob

Professor Irene Gottlob, Professor of Ophthalmology, Dept. of Neuroscience, Psychology and Behaviour, The University of Leicester Ulverscroft Eye Unit, Leicester Royal Infirmary Robert Kilpatrick Clinical Sciences Building PO Box 65 Leicester LE2 7LX, United Kingdom, ig15@le.ac.uk

Graf

Prof. Dr. Norbert Graf, Klinik für Pädiatrische Onkologie, Universitätsklinikum des Saarlandes, Kirrbergerstr. 100, 66424 Homburg, Germany graf@uks.eu

Gregory-Evans

Dr Cheryl Y Gregory-Evans PhD, Professor of Developmental Biology, Dept of Ophthalmology, Eye Care Centre, University of British Columbia, 2550 Willow Street, Vancouver B.C. V5Z 3N9, CANADA, cge30@mail.ubc.ca

Han

Prof. Dr. Joan C. Han, Associate Professor Pediatrics, Associate Professor Physiology, 454R Le Bonheur Research Center, 50 North Dunlap Street, Memphis, TN 381032893, USA jhan14@uthsc.edu

Käsmann-Kellner

Prof. Dr. Barbara Käsmann-Kellner, Universitäts – Augenklinik, Deutsches Aniridie Zentrum, Sektion KiOLoN, Kinderophthalmologie, Orthoptik, Low Vision, Neuroophthalmologie; Landesblindenärztin des Saarlandes; Campus, Geb. 22, D 66421 Homburg (Saar), Germany, kaesmann@gmail.com www.augenkinder.de

Lagali

Prof. Dr. Neil Lagali, Docent and Associate Professor, Experimental Ophthalmology Department of Ophthalmology, Institute for Clinical and Experimental Medicine, SE-581 83 Linköping, Sweden neil.lagali@liu.se

Latta

Dr. Lorenz Latta, Biologisches Labor, Klinik für Augenheilkunde, Universitätsklinikum des Saarlandes, Kirrbergerstr. 1, 66424 Homburg, Germany, lorenz.latta@uks.eu

Lauderdale

James D. Lauderdale, Ph.D., Associate Professor, The University of Georgia, Department of Cellular Biology, Paul D Coverdell Center, 500 DW Brooks Drive, Athens, GA 30602-7394, USA jdlauder@uga.edu

Lim

Hyun Taek Lim, MD, PhD., Professor, Department of Ophthalmology, Asan Medical Center, University of Ulsan College of Medicine, 388-1 Pungnap-dong, Songpa-gu, Seoul, Korea. htlim@amc.seoul.kr

Netland

Dr. Peter A. Netland MD, University of Virginia Department of Ophthalmology West Complex, 1300 Jefferson Park Ave, Charlottesville, Virginia VA 22903, USA pnetland@virginia.edu

Nguyen

Prof. Dr. Nhung Nguyen, Sektion Sehbehinderung, Universitäts-Augenklinik Tübingen, Schleichstr. 12, 72076 Tübingen, Germany, nhung.nguyen@med.uni-tuebingen.de

Osenger

Manfred Osenger, Governing Mayor of the city of Duisburg, Rathaus, Burgplatz 19, 47049 Duisburg, Germany m.osenger@stadt-duisburg.de

Poli

Barbara Poli, Vice President of Aniridia Europe, Delegate of Aniridia Italiana for AE, Venice, Italy. barbara.poli@aniridia.eu

Rohrbach

Prof. Dr. Jens Martin Rohrbach, Department für Augenheilkunde/Center for Ophthalmology, University of Tuebingen, Schleichstr. 12-16, D-72076 Tübingen, Germany Martin.Rohrbach@med.uni-tuebingen.de

Schlötzer-Schrehardt

Prof. Dr. Ursula Schlötzer-Schrehardt, University of Erlangen-Nürnberg, Department of Ophthalmology, Schwabachanlage 6, D-91054 Erlangen, Germany, ursula.schloetzer-schrehardt@uk-erlangen.de

Sanchez de Vega

Rosa Sanchez de Vega, Member of the Board of Directors, Aniridia Europe; Member of the Spanish Aniridia Association, Salamanca, Spain rosa.sanchez@aniridia.eu

Seitz

Prof. Dr. Berthold Seitz ML FEBO, Director, Klinik für Augenheilkunde, Universitätsklinikum des Saarlandes, Kirrbergerstr. 100, 66424 Homburg, Germany berthold.seitz@uks.eu

Sommer-Landsend

Dr. Erlend Sommer-Landsend, Overlege ved seksjon for pediatrisk oftalmologi og strabisme, Oslo Universitetssykehus, Ullevål, Oslo, Norway. xecsl@yahoo.no

Toews-Hennig

Denice Toews-Hennig, President, Aniridie-Wagr e.V. Support Group Germany, Georg-Friedrich-Händel-Str. 7, 96247 Michelau, Tel: 09571 - 97 38 575, Fax: 09571 - 97 38 364; info@aniridie-wagr.de www.aniridie-wagr.de

Trout

Kelly Trout, BSN, RN, Health Consultant, International WAGR Syndrome Association, www.wagr.org, San Antonio, Texas, USA kelly.trout@wagr.org

Utheim O

Dr. Øygunn Aass Utheim Department of Ophthalmology, University of Oslo, Norway Norwegian Dry Eye Clinic, Oslo/Fredrikstad/Tromsø, Norway outheim@gmail.com

Utheim TP

Dr. Tor Paaske Utheim MD PhD, Director of Innovation, Oslo University Hospital, Norway. Head of Unit of Regenerative Medicine, Department of Medical Biochemistry, Oslo University Hospital, Norway. Department of Oral Biology, Faculty of Dentistry, University of Oslo, Norway. Director of Research/Senior Consultant, Department of Ophthalmology, Vestre Viken Hospital Trust, Drammen, Norway. Professor, Faculty of Health Sciences, National Centre for Optics, Vision and Eye Care, University College of Southeast Norway, Norway. Adjunct Clinical Associate, Schepens Eye Research Institute, Massachusetts Eye and Ear, Department of Ophthalmology, Harvard Medical School, Boston, US. utheim2@gmail.com

Van den Bosch

Joeri Van den Bosch, Tax and legal adviser at KMO Consult, Putte, Flemisch Region, Belgium. joeri.van.den.bosch@aniridia.eu

van Heyningen

Prof. Dr. Veronica van Heyningen CBE FRS, Patron, Aniridia Network UK, Honorary Professor and Visiting Scientist Institute of Ophthalmology, University College London & MRC Human Genetics Unit Institute of Genetics and Molecular Medicine Edinburgh, United Kingdom, veronica.vanheyningen@aniridia.org.uk

Vasilyeva

Dr. Tatyana A. Vasilyeva, Federal State Budgetary Institution «Research Center for Medical Genetics», Moskvorechie Str., 1, Moscow 115478, Russian Federation. vasilyeva_debrie@mail.ru

Viestenz

Prof. Dr. Arne Viestenz, Klinik für Augenheilkunde, Universitätsklinikum des Saarlandes, Kirrbergerstr. 100, 66424 Homburg, Germany arne.vienstenz@uks.eu

ANIRIDIA ASSOCIATIONS IN EUROPE

sorted alphabetically according to country

ANIRIDIA BULGARIA	Bulgaria	http://aniridiabg.eu
Aniridia FINLAND	Finland	www.aniridia.fi
Association Geniris soutien aux personnes atteintes d'aniridie et de pathologies rares de l'iris	France	www.geniris.fr
AWS ANIRIDIE WAGR e.V.	Germany	www.aniridie-wagr.de
Aniridia Italiana	Italy	www.aniridia.it
ANIRIDI NORGE	Norway	www.aniridi.no

Российское Межрегиональное общество помощи и поддержки аниридийных больных ANIRIDIA.RU	Russia	www.aniridia.ru
Asociación Española aniridia "Colabora hoy, veremos mañana..."	Spain	www.aniridia.es
Aniridi Sverige	Sweden	www.aniridi.se
Aniridia Europe	Umbrella Association for all National Aniridia Associations	www.aniridia.eu
Aniridia Network UK	United Kingdom	www.aniridia.co.uk

The following countries have aniridia contact persons, who can be contacted via:
http://www.aniridia.eu/members/

- **Belgium**
- **Denmark**
- **Greece**
- **Iceland**
- **Poland**
- **Portugal**
- **Serbia**

Switzerland

If you have the chance, please donate to „Aktion Kinderaugen am UKS"

These charity activities aim at improving the care for visually impaired or blind children and for children who are multiply disables at the Department of Paediatric Ophthalmology & Low Vision and the German Aniridia Center at the University of Saarland.

We would like to expand our diagnostic and therapeutic tools, improve the accoutrements with Low Vision Aids to have better options to advise patients and to fit Low Vision Aids, and we want to create a more Low- Vision- orientated and barrier-free surrounding in our department.

Details and bank account information please see:

www.augenkinder.de

Thank you!

See you all again at the

4th European Aniridia Conference

in Paris, France, in 2018!!